

patients with systemic lupus erythematosus and antiphospholipid antibodies.

M F CORDEIRO
M E LLOYD
D J SPALTON
G R V HUGHES
*The Medical Eye Unit,
Department of Rheumatology,
St Thomas' Hospital,
London, UK*

Correspondence to: Mr D J Spalton, Medical Eye Unit, Lambeth Bridge Road, St Thomas' Hospital, London SE1 7EH, UK.

- 1 Levine SR, Welch KMA. Cerebrovascular ischaemia associated with lupus anticoagulant. *Stroke* 1987;18:257-63.
- 2 Beck RW, Cleary PA, Anderson MM, et al. A randomized, controlled trial of corticosteroids in the treatment of acute optic neuritis. *N Engl J Med* 1992;326:581-8.
- 3 Drosos AA, Petris CA, Petroustos GM, Moutsopoulos HM. Unusual eye manifestations in systemic lupus erythematosus patients. *Clin Rheumatol* 1989;8:49-53.
- 4 Herranz MT, Rivier G, Khamashta M, Hughes GRV. Epilepsy associated with antiphospholipid antibodies in systemic lupus erythematosus [abstract]. *Fifth international symposium on antiphospholipid antibodies*. San Antonio, Texas, 1992.
- 5 Lavalle C, Pizarro S, Drenkard C, et al. Transverse myelitis: A manifestation of systemic lupus erythematosus strongly associated with antiphospholipid antibodies. *J Rheumatol* 1990;17:34-7.
- 6 Asherson RA, Merry P, Acheson JF, et al. Antiphospholipid antibodies: A risk factor for occlusive ocular vascular disease in systemic lupus erythematosus and the "primary" antiphospholipid syndrome. *Ann Rheum Dis* 1989;48:358-61.
- 7 Galetta SL, Plock GL, Kushner MJ, et al. Ocular thrombosis associated with antiphospholipid antibodies. *Ann Ophthalmol* 1991;23:207-12.
- 8 Asherson RA. Subungual splinter haemorrhages: A new sign of the antiphospholipid coagulopathy. *Ann Rheum Dis* 1990;49:268-71.
- 9 Oppenheimer S, Hoffbrand BI. Optic neuritis and myelopathy in systemic lupus erythematosus. *Can J Neurol Sci* 1986;13:129-32.
- 10 Hess DC, Sheppard JC, Adams RJ. Increased immunoglobulin binding to cerebral endothelium in patients with antiphospholipid antibodies. *Stroke* 1993;24:994-9.

Cocaine induced chronic tics

Since the early 1980s, cocaine misuse has rapidly become more frequent with many users chronically taking large doses of this drug. Cocaine has been increasingly associated with ischaemic stroke, subarachnoid and intracerebral haemorrhage, seizures, migraine-like headaches, toxic encephalopathies, a fatal condition resembling neuroleptic malignant syndrome, and dystonia during administration and after withdrawal. It is also a risk factor for neuroleptic induced dystonia.¹ Some of these complications are caused by its powerful vasoconstricting effect. It also exacerbates the multifocal motor and vocal tics that are part of Tourette's syndrome.^{2,3} The first two cases of transient (< four months) new onset tic disorders were reported in 1990.² We describe a third patient, with no personal or familial history of Tourette's syndrome, who developed cocaine induced chronic tics over two years.

A 35 year old right handed woman was admitted for investigation of movement disorders which had developed over the two preceding years. She had an otherwise unremarkable medical record and no family

history of neurological disease. Her psychiatric history showed a personality disorder with aggression, hyperactivity, and episodes of depression with polydrug and alcohol misuse, having consumed marijuana, mescaline, LSD, and magic mushrooms from 12 to 17 years of age. There was no evidence of the presence of any symptoms of obsessive compulsive disorder or transient tics in childhood. She admitted to binge drinking of alcohol as well as regular and exclusive cocaine misuse for the past nine years. The patient took cocaine intranasally from 26 to 32 years of age, then she switched to "crack" for three years. She also took benzodiazepines during periods of cocaine abstinence. She had used the intravenous route on only one occasion. Her HIV serology test was negative two months before admission. Her symptoms consisted mainly of nostril flaring, arm jerks, grimaces, shoulder shrugging, grunting, and head jerks that had progressively increased in frequency and severity. These movements had not disappeared for more than a few hours since the onset. They were mostly brief and jerky but more prolonged movements also occurred, and were exacerbated by anxiety or temporarily suppressed voluntarily (for example, when waiting for a job interview). Neurological examination showed, in addition to the tics already described, a mild cogwheel rigidity of the right arm. Tics were not more prominent in either extremity. The patient had no other symptoms and was not taking medication. She presented an acute episode of exacerbation after her return from a weekend leave during which she had misused both alcohol and cocaine. She had complex tics with coordinated abnormal movements involving her entire body, including eye deviation and rolling, facial contortions, and plaintive vocal sounds. She was also hyperactive, impulsive, and mutilated herself (right fingers). The abnormal movements disappeared briefly (five minutes) when she ate, and decreased to the basal level after one day.

Her routine blood biochemistry was normal, as was her EEG. Her CSF proteins were slightly increased (548 mg/l). A CSF venereal disease test was negative. CSF homovanillic acid (HVA) was 26.1 ng/ml, 5-hydroxyindoleacetic acid (5HIAA) was 16.9 ng/ml, and 3-methoxy-4-hydroxyphenyl-ethylene glycol (MHPG) was 38.7 ng/ml (normal CSF values of biogenic amines were obtained in 15 age matched controls with lumbar disc herniations. These were: HVA 48.2 (SD 10.1) ng/ml, 5HIAA 22.8 (6.8) ng/ml, and MHPG 11.8 (5.4) ng/ml). ^{99m}Tc-HMPAO SPECT showed focal regional cerebral blood flow hypoperfusion in the bilateral anterofrontal (pronounced on the right side) and parieto-occipital cortex, left temporal and cerebellar cortex, and right basal ganglia. Brain CT showed no focal or general atrophy. The only abnormality was dilatation and elongation of the right vertebral and basilar arteries. Against medical advice, she refused treatment and hastily left the hospital two weeks after admission, during which tics were always present. Neuropsychological evaluation was incomplete and no firm conclusions could be drawn.

Pascual-Leone and Dhuna reported two cases of transient new onset tic disorders after a high dose of cocaine in two habitual

cocaine misusers. Neither had a personal or family history of tics. After taking an unusually large dose of cocaine intranasally and intravenously, these two women presented multifocal motor and vocal tics. The tics resolved over several weeks to four months.² Our patient seems to be the first case who developed new onset chronic (two years) multifocal motor and vocal tics with chronic cocaine misuse. She took many other drugs from age 12 to 17, but her consumption was virtually limited to cocaine from age 26 to 35 (intranasally for six years and "crack" cocaine for three years). Alcohol (which is also misused by our patient) misuse or alcohol withdrawal is not associated with tics despite its well known toxic effects.³ In this patient the tics were clearly exacerbated by high dose cocaine use. The hyperactivity syndrome presented in the past by our patient could be related to Tourette's syndrome and could represent an alternative phenotype for the putative Tourette's syndrome gene that might have been predisposing this patient to cocaine. This remains speculative, however.

In our patient SPECT showed multifocal abnormalities of regional cerebral blood flow. This may represent the consequence of regional functional damage, directly resulting from vasospasm or indirectly by potentiating the physiological response to cocaine, or subclinical cerebral vasculitis.¹ Irregularity of the right vertebral artery perhaps favours the second hypothesis. The discrete right extrapyramidal hypertonia may have been induced by some of these focal abnormalities. In 16 of 18 cocaine dependent polydrug users, focal abnormalities of regional blood flow were mainly seen in the inferior parietal cortex, temporal cortex, anterofrontal cortex, and basal ganglia.⁴ The major symptoms (multifocal tics) in our patient were not lateralised, however, and did not favour this haemodynamic or structural interpretation.

Many neurotransmitter systems have been implicated but only the dopaminergic (DAergic), noradrenergic (NAergic), opioid, and GABAergic systems have shown consistent abnormalities, and no primary system has emerged in the pathophysiology of tic disorders. Imbalances within different inter-related neurotransmitter systems could produce these symptoms.⁵ Cocaine is a known reuptake blocker of the DAergic and NAergic systems. Chronic cocaine consumption leads to depletion of presynaptic dopamine and noradrenaline stores and may induce postsynaptic receptor hypersensitivity. Some studies have shown lower CSF HVA concentrations in patients with tics compared with controls, which return to normal with successful neuroleptic drug treatment.⁵ The clinical evidence in favour of the DAergic hypothesis is summarised by Lang⁶: (a) dopamine receptor antagonists are most effective in suppressing tics; (b) tics often increase with drugs that enhance dopamine neurotransmission (for example, amphetamine); (c) tics may occur as part of tardive dyskinesia (rare). CSF HVA was low in our case, indicating that the DAergic system may play a major part in this disorder. It is interesting to note that the use of amphetamine (which seems to cause release of dopamine as well as blocking its reuptake leading also to depletion of striatal dopamine and to hypersensitivity of dopamine receptors) is known to induce repetitive stereotypic dyskinesia and may

aggravate pre-existent movement disorders such as Tourette's syndrome and chorea,³ or provoke tics in patients with attention deficit hyperactivity disorders.⁵ These amphetamine mediated phenomena are similar to those induced by cocaine except for the stereotypic dyskinesia. In regard to the NAergic system, there were no biochemical abnormalities in the cortex and basal ganglia.⁵ Clonidine, an α_2 -adrenergic agonist, reduced tics, however, through a direct effect or indirectly by modulating mesolimbic neurons containing dopamine. CSF MHPG in our case was paradoxically high, showing a complex imbalance between neurotransmitter systems that is only partially detected by CSF metabolites. Some findings (cited by Lang⁶) reported variable implications of opioid and GABAergic systems in the pathogenesis of Tourette's syndrome. Opiate antagonists may lessen tics, whereas withdrawal of chronic opiate treatment may worsen this condition. There are some responses to benzodiazepines (clonazepam). Implications of other neurotransmitter systems are cited in the literature but these findings are not consistent.⁵ Further controlled studies using SPECT or PET, CSF biogenic amines, possibly concentrations of cocaine in blood or CSF, and neuropsychological testing results are needed to better identify deficiencies after cocaine misuse.

EZZEDINE ATTIG
ROBERT AMYOT
THERÈSE BOTEZ
Department of Neurology,
Hôtel-Dieu Hospital
affiliated to the University of Montréal,
P Québec, Canada

Correspondence to: Dr E Attig, Department of Neurology, Hôtel-Dieu Hospital, 3840 St Urbain, Montréal, Québec, Canada H2W 1T8.

- 1 Rodnitzky RL, Keyser DL. Neurologic complications of drugs—tardive dyskinesias, neuroleptic malignant syndrome, and cocaine-related syndromes. *Psychiatr Clin North Am* 1992;15:491-510.
- 2 Pascual-Leone A, Dhuna A. Cocaine-associated multifocal tics. *Neurology* 1990; 40:999-1000.
- 3 Cardoso F, Jankovic J. Movement disorders. In: Brust JCM, ed. *Neurologic complications of drug and alcohol abuse*. *Neurol Clin* 1993; 11:625-38.
- 4 Holman LB, Carvalho PA, Mendelson J, et al. Brain perfusion is abnormal in cocaine-dependent polydrug users: a study using Tc-99m-HMPAO and SPECT. *J Nucl Med* 1991;32:1206-10.
- 5 Singer HS, Walkup JT. Tourette syndrome and other tic disorders: diagnosis, pathophysiology and treatment. *Medicine* 1991; 70:15-32.
- 6 Lang AE. *Tics and Tourette syndrome*. In: Jankovic J, director. *Movement disorders course No 440*. San Diego CA: American Academy of Neurology, Annual Meeting, 3-9 May 1992:123-45.

"Ease of falling" syndrome associated with subdural haematoma

The "ease of falling" syndrome refers to acute onset contralateral postural deficits secondary to acute lesions of the unilateral basal ganglia. Previously reported cases¹⁻⁶ had intracerebral lesions affecting the basal ganglia. The present case is unique as the patient developed the syndrome secondary to an extracerebral lesion in the form of a subdural haematoma.

A 65 year old ex-policeman was admitted with a three day history of falling to his right whenever he attempted to sit, stand, or walk. He was normal until a day before the onset of this neurological event when he had complained of a mild generalised throbbing headache. The next morning he noticed difficulty in getting out of bed and needed support to even sit erect. He was unable to stand or walk without support. Whenever he attempted to do so he leaned heavily to his right and fell over. He had never experienced such an event in the past. There was no history of drugs that could produce extrapyramidal syndrome or ataxia. He gave no history of head trauma. He was not a diabetic and was not hypertensive.

On admission his blood pressure was 140/80 mmHg and his heart rate was 90 beats/min. The cardiovascular system was normal. There were no external injuries. He was conscious and well orientated to his surroundings. Speech and memory were normal. His pupils were normal in size and reacted equally well to light. He had a mild drift of the outstretched right arm. Power of the other limbs was normal. Muscle tone was normal in all limbs. The deep tendon reflexes were hyperactive on the left side. The Babinski's reflex was flexor on both sides.

His tendency to fall to his right was obvious and striking. He was unable to sit, stand, or walk without support. When asked to rise from a recumbent posture he would grapple at the cot railings with his left hand and struggle to do so. When supported he could sit erect for a few seconds but gradually leaned to his right and diagonally backwards. When helped to stand erect, he would fall in the same direction. Supported walking was possible for only a few steps and was terminated by the falling attack. Another striking feature was that he made no postural adjustments to overcome such falls and barely expressed concern about them (figure; left).

He had no evidence of hemianaesthesia or visual field cut. Bedside tests for sensory neglect were negative. His right arm was underused in motor tasks. This was out of proportion to the mild weakness of that limb, indicating the presence of motor

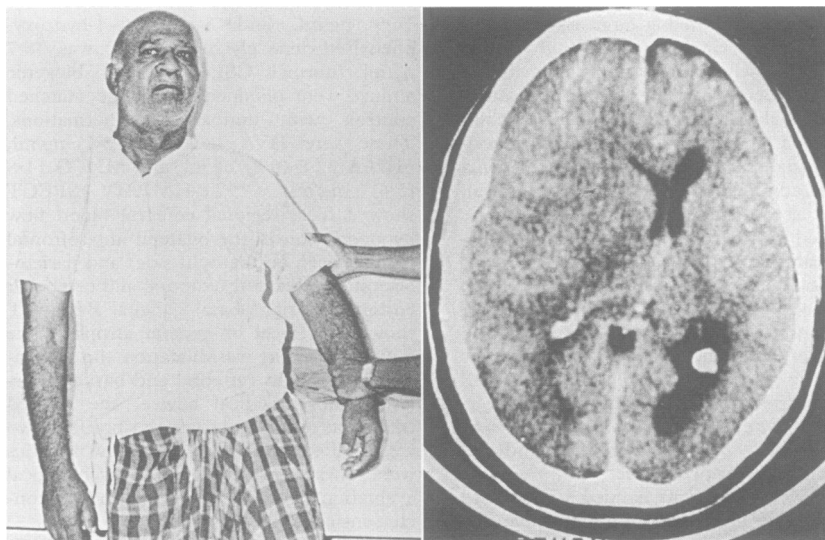
neglect as well as the pyramidal lesion. He had no features of cerebellar, vestibular, or peripheral nerve disorder.

A clinical diagnosis of "ease of falling" syndrome was made. A plain and contrast enhanced CT of the head surprisingly showed a large subdural haematoma in the left frontoparietal region (figure; right). The haematoma was isodense with the cortex and compressed the ipsilateral subcortical structures and lateral ventricle and produced a shift of the midline structures to the opposite side. There was no evidence of damage to the underlying brain. Chest radiograph, ECG, and carotid Doppler studies were normal. Blood chemistry was normal. Serological tests for syphilis were negative.

A burrhole was made on the left side of the skull and 250 ml of altered blood was evacuated under local anaesthesia. The result was dramatic. The patient could sit erect without support in the immediate postoperative hours. Detailed evaluation was carried out over the next 24 hours and photographically documented. He could sit erect, stand, and walk by himself without any tendency to fall. The outstretched right arm showed no drift. The pyramidal signs and motor neglect disappeared.

The "ease of falling" syndrome has become well characterised through the studies of Masdeu and Gorelick,⁴ Awerbuch *et al.*,⁵ and Labadie *et al.*⁶ Isolated cases with similar features had already been reported by Fisher and Cole¹ in 1965 and by Fisher in 1979 and 1982.^{2,3} As noted by all these authors the falls are a contralateral slow tilting motion either laterally or diagonally backwards. The patient shows lack of awareness and does not make postural adjustments to avoid the fall. Criteria require that the patient should exhibit such falling events in the absence of significant hemiparesis, hemianaesthesia, cerebellar ataxia, vestibular dysfunction, proprioceptive loss, and peripheral nerve disorder. Our patient qualifies for the diagnosis of this syndrome.

All previously reported cases had an intracerebral lesion affecting either the putamen, pallidum, or the thalamus, Lacunar infarcts and haemorrhages are the only lesions that have produced this acute



(left) The patient falling to his right and diagonally backwards. Note the lack of concern about the fall; (right) CT showing a large left frontoparietal subdural haematoma.